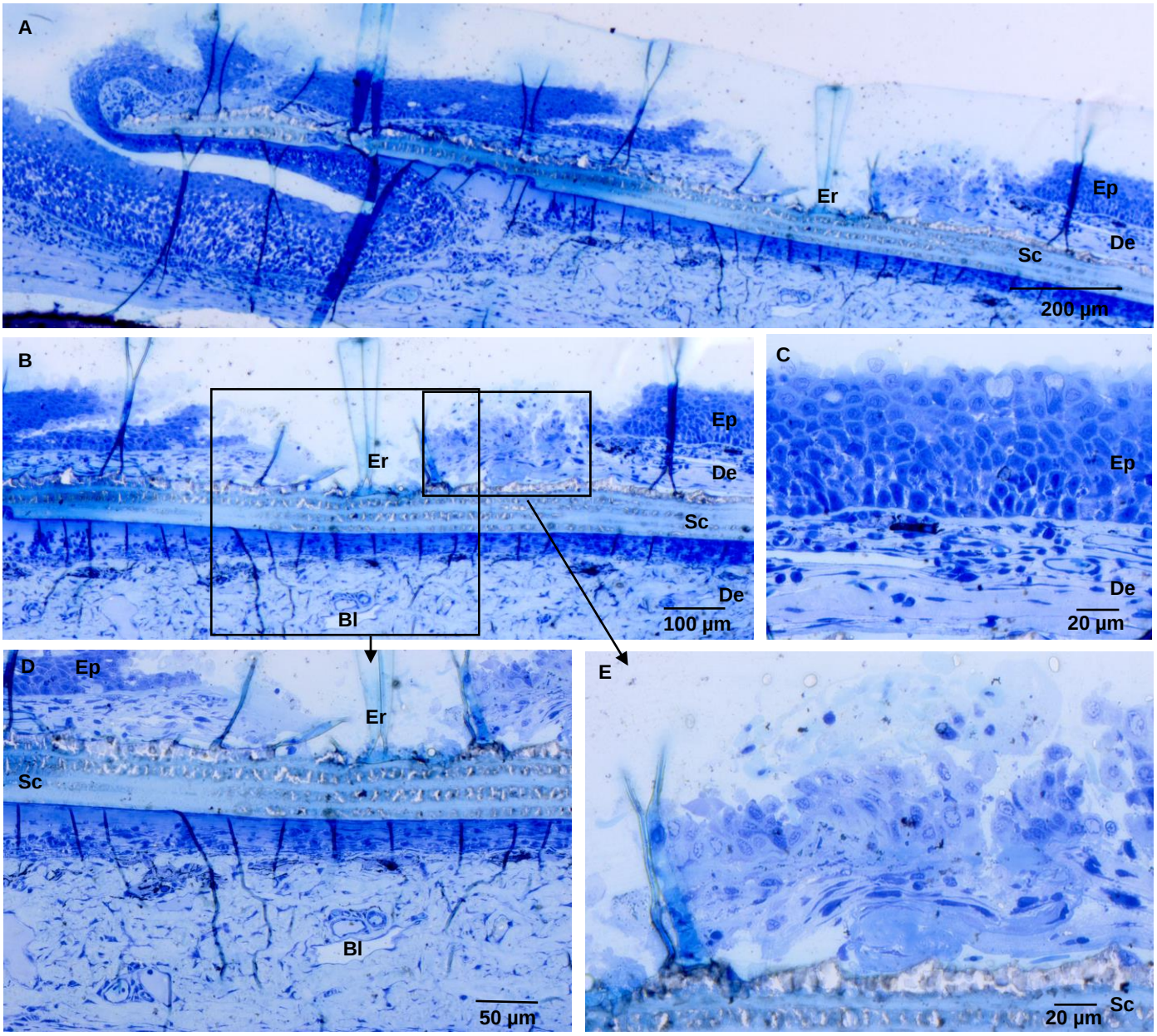


**Supplementary figure 1:** Histopathology in Atlantic salmon scaled skin infested with adult lice at the skin attachment site from plastic embedded sections stained with toluidine blue. The images are of the same specimen with different magnification, and the proposed erosion (Er) site from the mouth tube is seen (A, B, D, E), with some (E) necrotic tissue. (C) posterior the erosion site. Folding in the specimen are artifacts from sample preparation. All abbreviations: Ep - epidermis, De - dermis, Sc – scale, Er – erosion, Bl – blood vessel.